

AN OBSERVATIONAL STUDY TO EVALUATE BENEFITS AND OUTCOME OF ULTRASOUND GUIDED FOAM SCLEROTHERAPY IN VARICOSE VEINS

Priti Batra¹, Paras Kumar Pandove², Darshanjit Singh Walia³, Dheeraj Manchanda⁴

Received : 12/06/2023
Received in revised form : 17/07/2023
Accepted : 28/07/2023

Keywords:
Varicose Veins, UGFS, Local and Systemic Complications, Outcomes.

Corresponding Author:
Dr. Priti Batra,
Email: priti0149@gmail.com.

DOI: 10.47009/jamp.2023.5.4.334

Source of Support: Nil,
Conflict of Interest: None declared

Int J Acad Med Pharm
2023; 5(4); 1682-1685



¹FNB-MAS Department of Surgical Gastroenterology /Bariatric and Minimal Access Surgery, BLK MAX Super Speciality Hospital, New Delhi, India.

²Professor, Department of Surgery, Government Medical College, Patiala, India.

³Professor, Department of Surgery, Government Medical College, Patiala, India.

⁴Fellow in Liver Transplant, Institute of Liver Transplant and Regenerative Medicine, Medanta, Gurgaon, India.

Abstract

Background: Aims: The aim of the study is to evaluate Ultrasound-Guided Foam Sclerotherapy (UGFS) as a treatment option for varicose veins in a set up where other more effective options like Endovenous Laser Ablation (EVLA) & Radiofrequency Ablation (RFA). Settings and Design: A prospective observational study was done on 30 patients with varicose veins in the Department of General Surgery, Government Medical College & Rajindra Hospital, Patiala. **Materials and Methods:** Patients with varicose veins were treated with UGFS using sodium tetradecyl sulphate under Ultrasound guidance using Tessari's method and were observed for local & systemic complications & recurrence. Statistical analysis used: Performed using Statistical Program for Social Sciences (SPSS) software version 20.0 Chicago, Illinois, USA. AI. For categorical variables, chi-square test was used for analysis. **Results:** Out of 30 patients, primary GSV occlusion was seen in 28 patients (93%). A minimum one and maximum of three sessions were required for GSV occlusion. 28 patients (93%) were symptomatically relieved. Out of 5 patients who had venous ulcers, healing was seen in 4 (80%). Post-procedure localized pain was experienced by 13 patients (43%), 6 patients (20%) had superficial thrombophlebitis & 10 patients (30%) had skin pigmentation. There was no incidence of any major complication. Recurrence was reported in 3 patients (10%). **Conclusion:** UGFS can be concluded as a safe, effective, well tolerated, and satisfactory procedure for the management of varicose veins and associated venous ulcers.

INTRODUCTION

Varicose veins are defined as dilated and tortuous subcutaneous veins measuring >3 mm in diameter in upright position in which reflux is demonstrable.^[1] Venous hypertension is the underlying pathophysiology contributed to by various causes like obesity, pregnancy, valvular incompetence, loss of vein wall compliance, etc. To account for multifactorial etiology and heterogenous clinical presentations.^[2] CEAP classification system and scoring systems like venous clinical severity scoring system (VCSS) and venous segmental disease score (VSDS) were devised so as to help in having uniform treatment plans & study treatment outcomes. We used CEAP classification in our study.^[3]

In 1942 Orbach described a method of making foam or froth with the solution. He claimed that this increased the efficacy of injection treatment. This method was used by a small number of surgeons but never found a great following.^[4] Sclerotherapy as a treatment modality involves introducing a chemical substance into a vessel to cause thrombosis followed by fibrosis. The sclerosing agents damage the endothelium of the vessels wall.^[5] This damage causes the fibrosis and the extent of this damage is proportional to the effectiveness of the therapy. In use for over 100 years, sclerotherapy is the original non endothermal and non-tumescent technique.^[6] Using foamed sclerosant has various advantages over liquid sclerosant. The most widely used method is that of Tessari.^[7] The injected foam displaces blood in the vessel. This prevents the dilution and inactivation of the sclerosing agent.

Foam has greater surface area & volume. So it fills more of the vein and has a greater ability to sclerose. Also the foam is visible on Duplex ultrasound & can be steered in desired direction with the help of ultrasound probe, thereby leading to the development of Ultrasound-Guided Foam Sclerotherapy.

This study was done to evaluate Ultrasound-Guided Foam Sclerotherapy (UGFS) as a treatment option for varicose veins in a set up where other more effective options like EVLA& RFA.

MATERIALS AND METHODS

Ours was prospective observational study conducted on 30 patients of either sex in Department of General Surgery, Government Medical College & Rajindra Hospital, Patiala, Punjab. Patients were treated with sodium tetradecylsulphate foam prepared with a three-way tap and two plastic disposable syringes, using Tessari's method under ultrasound guidance. Patients of all age groups and with varicose veins at any level - CEAP classification C2-6EpAsPr were included in the study.

Patients with any history of allergy to the sclerosant substance, acute deep vein thrombosis or pulmonary thromboembolism, local infection in the area of sclerotherapy or severe systemic infection, prolonged immobilization, symptomatic patent foramen ovale, pregnancy and peripheral arterial occlusive disease were excluded.

All patients were assessed clinically for the presence & severity of varicose veins & associated venous ulcers & for the presence of edema, inflammation, hyperpigmentation, lipodermatosclerosis. Patients were examined by Duplex ultrasound to know the site of reflux along GSV.

Procedure

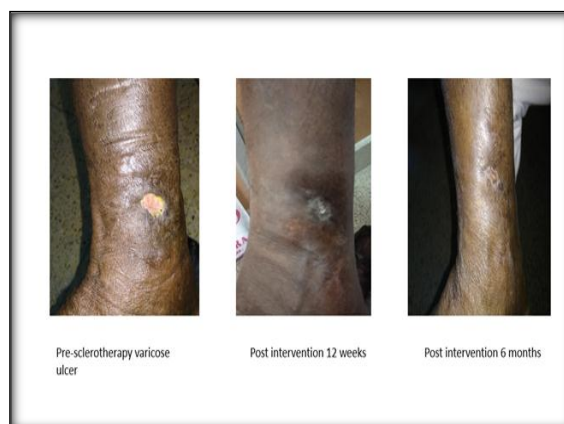The procedure was performed in Department of Radiodiagnosis under all aseptic measures & precautions after taking informed consent. The patient was positioned in supine position. Affected vein was traced and cannulated under DUS guidance. After emptying the cannulated vein by elevating the limb, the foam of STS prepared by Tessari method was injected whilst watching its progress by DUS. Injection was given proximally first & then distally. Foam was injected in 2ml aliquots, and its distribution and resultant venous spasm was observed by DUS. At least 30 seconds gap was given between injecting each aliquot of foam. After each injection patients were asked to dorsiflex and plantar-flex their ankle several times to clear any foam that might have entered the deep venous system. On completion of a and covered with class II compression stockings immediately. The bandage was advised to be worn for 7-10 days. Patients were followed up clinically and by DUS at the interval of 2 weeks to check for any DVT and need for further

sessions and at 3 months to evaluate success and recurrence.

RESULTS

Between January 2017 to August 2018 30 patients who reported in Rajindra hospital and GMC Patiala underwent ultrasound guided foam sclerotherapy. The mean age of patients was 41.30 ± 15.713 years. Numbers of females in study group were 10 (33.3%) and males were 20(66.7%) with Male to female ratio of approximately 2:1. Patients were classified on the basis of CEAP classification with 6(20%) patients from class C2a and 16(53.3%) from class C2s cumulative 22(73%) patients were from class C2. There were 3(10%) patients from class C4a and 5(16.7%) patients from class C6s.

In our study group 14 (46.6%) presented with pain. 22(73.3%) patients had complaints of heaviness. 13(43.3%) patients had complaints of swelling. 8(26.7%) patients had complaints of itching. 8(26.7%) patients had complaints of skin pigmentation. 7 (23.3%) patients had complaints of eczema and 5(16.7%) patients had venous ulcer, out of which 4(80%) patients reported significant improvement in ulcer healing and 1(20%) patient reported no improvement. 3 patients were found to have recurrence at 3 months follow up. Out of these 3 patients, 2 had single session and 1 patient had 2 sessions of UGFS.



In our study group patients were treated with variable amount of air mixed with sclerosant foam. Out of 30 patients 7 ml of foam was required in 2 (6.7%) to achieve complete occlusion, 20ml was required in 2 patients, 8 ml was required in 8 patients, 10 ml was required in 12 patients, 15 ml was required in 5 patients, and 16 ml was required in 1 patients in multiple sessions with a mean of 7.3 ml and a range of 7 to 20 ml.

In our study, No. of patients with above knee varicose veins were 10(33.3%) and below knee varicose veins were 20(66.7%). Out of 10 8 had GSV occlusion after multiple sessions and 2 showed reflux. All 20 patients with below knee varicose veins showed complete eradication of reflux.

Out of 30 patients 15 (50%) showed GSV occlusion and 15(50%) showed no GSV occlusion at 2 weeks. 28(93.3%) showed GSV occlusion and 2(6.7%) showed no GSV occlusion at 3 months, 15 (50%) patients felt symptomatically better at 2 weeks after single session of UGFS . 28(93.3%) felt symptomatically better at 3 months after one or more session of UGFS . 2 (6.7%) patients had no symptomatic relief at the end of 3 months follow up. out of 30 patient who were treated with UGFS.(fig.1)

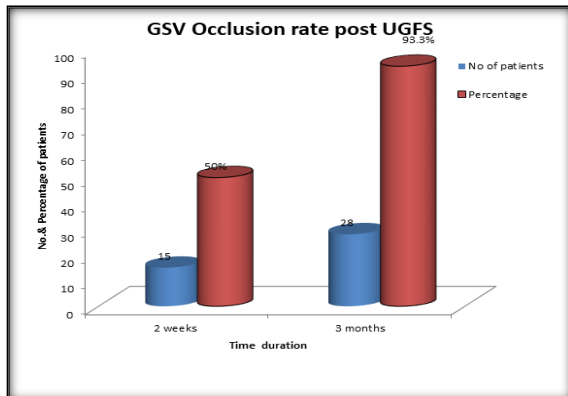


Figure 1: shows GSV occlusion at 2 weeks and 3 months post UGFS

In our study group, out of 30 patients, 8 (26%) patients had saphenofemoral junction incompetence, who were treated with UGFS in multiple sessions. Out of these 8 patients, 1 patient had GSV occlusion at 2 weeks, further 5 patients had GSV occlusion at 3 months post sclerotherapy. Thus, total 6 patients had occlusion of GSV with saphenofemoral junction incompetence after 3 months and no GSV occlusion was seen in 2 patients even after 3 months. Remaining 22 (74%) patients had competent SFJ pre sclerotherapy.

Out of 30 cases 15 patients were treated in single session and their cost of treatment was approximately in range Rs 500-750. 12 patients were treated in 2 sessions and their cost of treatment was approximately Rs 750-1000, while 3 patients were treated in 3 sessions and their cost of treatment was >Rs 1000. With no of sessions cost of treatment increased, with a significant cost difference (p value=.000).

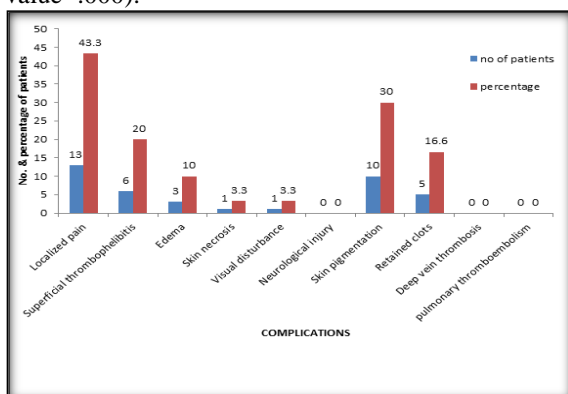


Figure 2: Shows frequency of complications post UGFS

In our study, 30 patients were treated with UGFS , out of which 13 (43.3%) patients reported localized pain , 6 (20%) patients reported superficial thrombophlebitis , 3 (10%) patients reported edema , 10(30%) patients reported skin pigmentation, 5(16.6%) patients reported retained clots , 1(3.3%) patients reported skin necrosis and 1 (3.3%) patients reported visual disturbance but no patient reported neurological injury , or deep vein thrombosis , or pulmonary edema.(Fig.2).

DISCUSSION

Varicose veins disease is usually over looked due to avoidance of magnitude and severity of the problem. Over last several years, there have been many attempts made to treat this condition optimally, by conservative, surgical or minimally invasive techniques. In country like India, varicose veins surgery remains the most common treatment .Varicose veins surgery is not considered to be a perfect treatment due to risk of neurological injury and unsatisfactory outcome and risk of damage to femoral artery. Sclerotherapy is defined as a procedure for treatment of varicose veins by minimal intervention, where asclerosant is injected into the lumen of the vein to produce endothelial damage and subsequent fibrosis , it not only reduces the size of treated vein and but also convert it into small fibrous cord, effective sclerotherapy also treats the pathophysiological reflux associated with the varicose veins. Based on 69 studies in systemic review done by Jiaet al.^[8] the median rate of target vein occlusion was 87% (range 60-98) . There were 2 indianstudies conductedby Mishraet al.^[9] and Maurya et al.^[10] reported 28/30 (93.3%) GSV occlusion in UGFS group (P value >0.05) and 100% success rate as an early outcome respectively.In our study the GSV occlusion rate was 50% at 2 weeks follow up , those patients who did not had complete occlusion were subjected to second session of sclerotherapy and out of remaining 15 (50%) patients ,in 12(40%) patients GSV occlusion was achieved in second sessionof UGFS and remaining 3(10%) patients were subjected to third session of sclerotherapy and the patients were followed up , 28 (93%) patients showed GSV occlusion and symptomatic relief at the end of 3 months with multiple sessions of sclerotherapy.In our study 5 patients who had varicose venous ulcer 4 (80%) patients showed good ulcer healing and 1 showed poor healing based on its unfavourable location (AK) and persistent GSV reflex which was comparable to study conducted by Darvellet al.^[11]

Jiaet al.^[7] reported that the median event rates were less than 1%. Median rate for visual disturbance was 1.1%, headache (4.2%), thrombophlebitis (4.7%), skin matting /skin staining /pigmentation (17.8%) and pain at the site of injection (25.6%).

Compared to surgery, FS was associated with higher risk of skin pigmentation (RR 1.41, 95% CI 1.07 to 1.85). An Indian study conducted by Mishra et al⁸ reported post-procedural pain as most common side effect in 50% patients in the UGFS group, intensity of pain as well as duration were shorter (1–2 days) in UGFS. In RFA group patients, 09.68 % (03/31) complained of cannulation site numbness. 50% (15/30) patients of UGFS group had cord-like induration along the GSV, which spontaneously resolved with compression bandage. Thrombophlebitis occurred in 26.67 % (8/30) of the patients in the UGFS group

No patient developed DVT.^[10] of the 148 legs developed superficial vein thrombosis (6.75%). In our study, out of 30 patients 13 (43.3%) patients had localized pain, 6 (20%) patients had superficial thrombophlebitis, 10(30%) patients reported skin pigmentation, 5(16.6%) patients reported retained clots, 1(3.3%) patients reported skin necrosis and 1 (3.3%) patients reported visual disturbance with slightly higher incidence of thrombophlebitis reported which is comparable to M.K.Mishra et al and Jia et al whereas no major complication like neurological injury, or deep vein thrombosis, or pulmonary edema was reported in our study.

Another aspect of our study was to observe and analyse the cost of the procedure. Giving increasing fiscal constraints, procedural cost effectiveness has become an important component in treatment procedures. Cost analysis comparing various treatment modalities is a difficult task. Accurate estimation of cost includes cumulative cost of all procedural, hidden and indirect costs. In our study the average cost of treatment per person is approximately Rs 849 which is comparable to the estimated cost (Rs 800) of treatment in UGFS by catheter group reported in an Indian study Mishra et al⁶. Mishra et al.^[6] compared the cost of UGFS by catheter with RFA which was 50 times less than that of RFA group.

CONCLUSION

Ultrasound guided foam sclerotherapy does not need any additional setup, except for a DUS, as this

facility is available in all the major hospitals of our country, the treatment cost becomes very economical and thus making UGFS a safe, effective and more importantly a well-tolerated procedure with satisfactory outcome for management of varicose veins. As it is done as an OPD procedure, so there is no need of hospital stay, with early return to work and with less cost of treatment as compared to other surgical as well as non-surgical treatment modalities. So, this form of therapy can be used as gold standard treatment of below knee varicose with competent SFJ with more effectivity.

REFERENCES

1. Chetter I, Carradice D. Bailey & Love's short practice of surgery. 27th ed. London: Chapman & Hall Medical; 2018. Chapter 57, Venous disorders; p. 901-923.
2. Chetter I, Carradice D. Bailey & Love's short practice of surgery. 27th ed. London: Chapman & Hall Medical; 2018. Chapter 57, Venous disorders; p. 969-72.
3. Singh S, Lees T, Donlon M, Harris N, Beard J. Improving the preoperative assessment of varicose veins. *British Journal of Surgery*. 1997;84(6):801-802.
4. Orbach EJ, Petretti AK. The thrombogenic property of foam of a synthetic anionic detergent. *Angiology*. 1950;1:237-243.
5. Sadick N. Choosing the Appropriate Sclerosing Concentration for Vessel Diameter. *Dermatologic Surgery*. 2010;36(Sup 2):976-981.
6. Orbach EJ. Sclerotherapy of varicose veins: utilization of intravenous airblock. *Am J Surg*. 1944;66:362-366.
7. Tessari L, Cavezzi A, Frullini A. Preliminary Experience with a New Sclerosing Foam in the Treatment of Varicose Veins. *Dermatologic Surgery*. 2001;27(1):58-60.
8. Jia X, Mowatt G, Burr JM, Cassar K, Cook J, Fraser C. Systematic review of foam sclerotherapy for varicose veins. *Br J Surg* 2007;94:925e36.
9. Mishra MK, Soni RK, Mohil RS, Sinha A. Comparative Study of Outcome of Duplex Ultrasound-Guided, Catheter-Directed Foam Sclerotherapy and Radio-frequency Ablation in the Management of Great Saphenous Varicose Veins. *The Indian journal of surgery*, (2016) 78(5), 375-381.
10. Maurya A, Sachdeva V, Nath B, Gupta P, Singh S, Verma S. Outcome of ultrasound guided foam sclerotherapy treatment for varicose veins: procedure is standard and need no further study. *Indian Journal of Vascular and Endovascular Surgery*. 2015;2(3):96.
11. Pang K, Bate G, Darvall K, Adam D, Bradbury A. Healing and Recurrence Rates Following Ultrasound-guided Foam Sclerotherapy of Superficial Venous Reflux in Patients with Chronic Venous Ulceration. *European*.